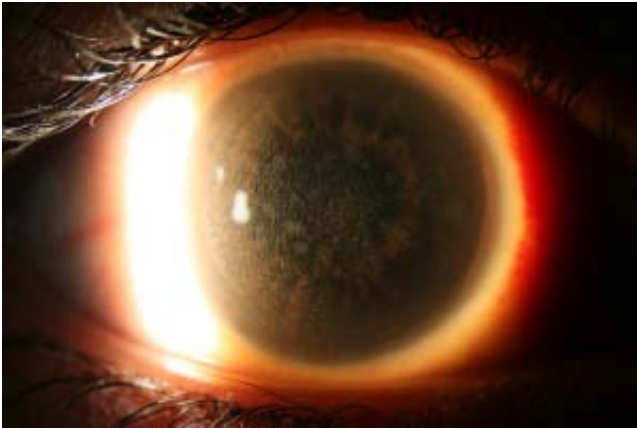


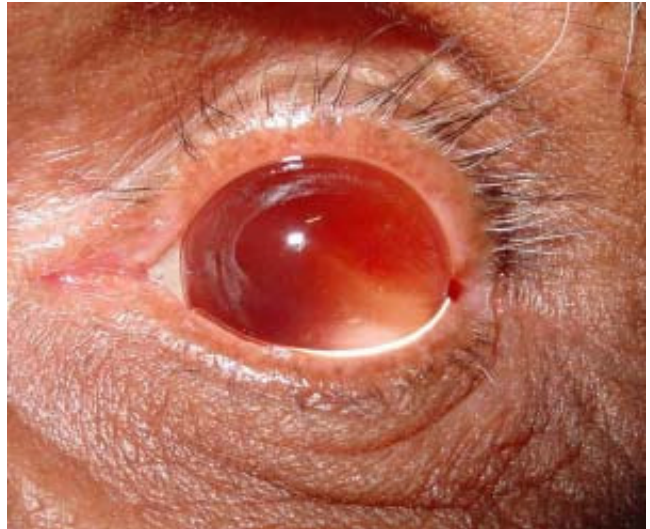
Photo Quiz

*Dr Ayan Mohanta, Dr Paromita Sanatani , Dr Arnab Biswas,
Dr Supratik Sanatani, Dr Vivek Dutta, Dr Arup Bhaumik*



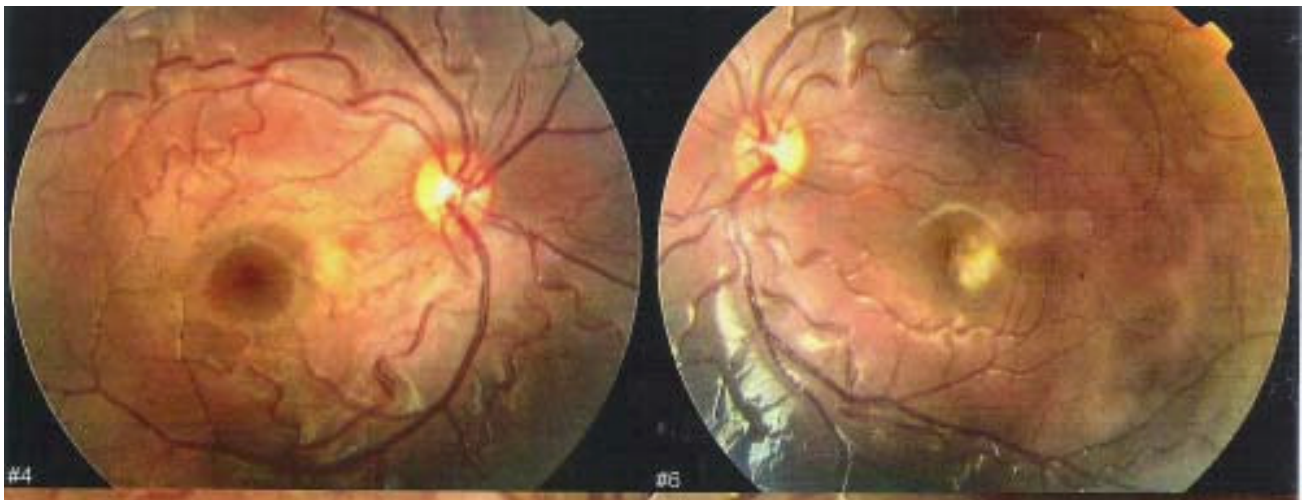
Q1. This is the slit lamp photograph of a post operative Lasik patient (day 2), the patient came to us with irritation, photophobia and mild dimness of vision. What slit lamp examination method is employed to view the cornea? What is the clinical diagnosis and treatment?

(Courtesy Dr Ayan Mohanta- Disha Eye Hospital)



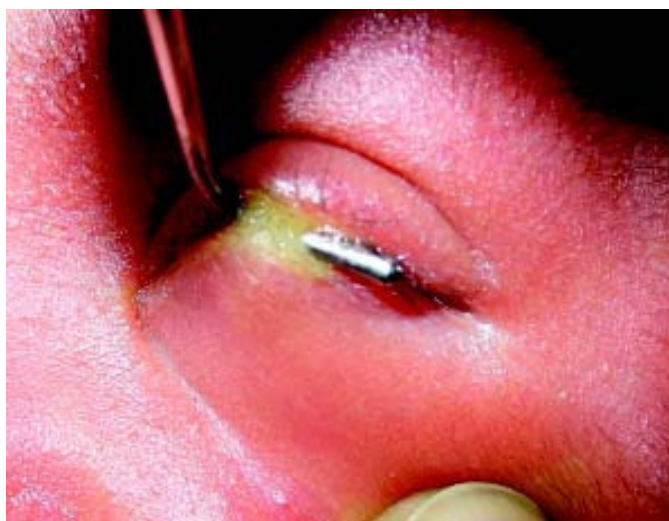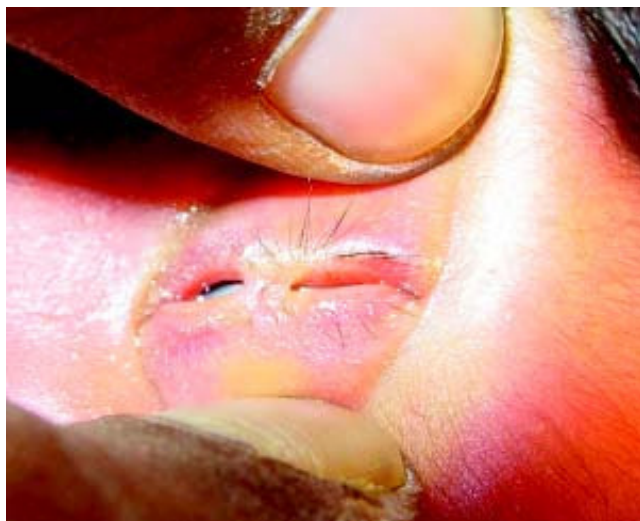Q2. What can you see?

(Courtesy Dr Arnab Biswas - Alo Eye Care)

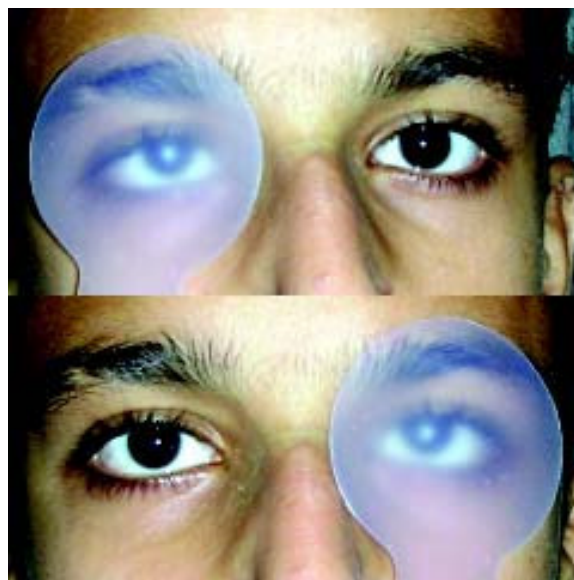
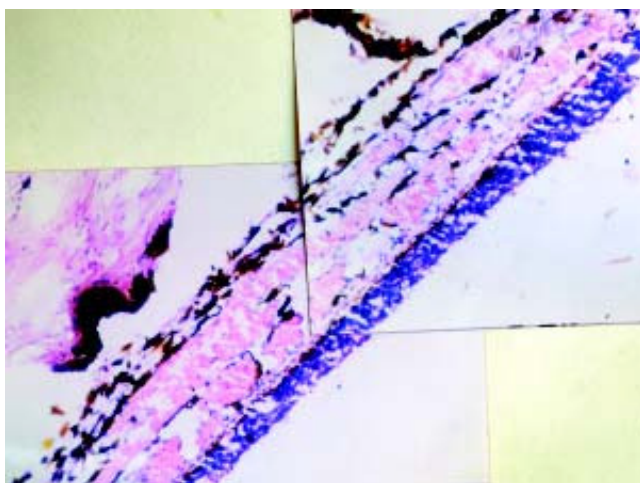


Q3. This is the fundus photograph of a young girl who presented with a squint since birth. What sort of ocular muscle anomaly would you expect?

(Courtesy Dr Paromita Sanatani - Athena Eye Care)



Q4. What is the Diagnosis? (Courtesy Dr Arnab Biswas)

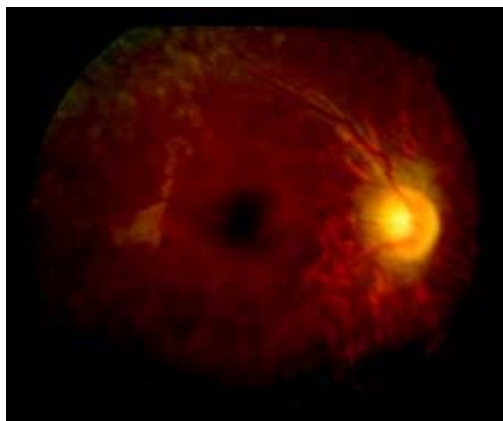
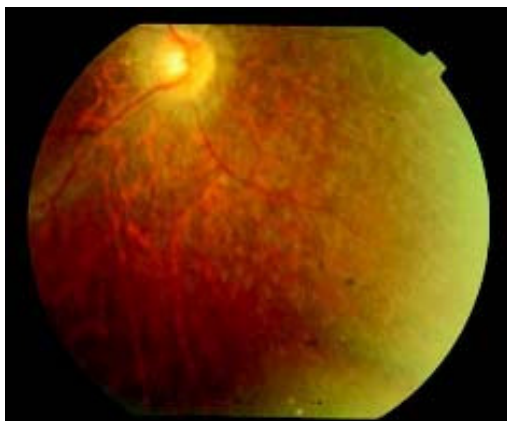


Q5. This is a relatively unusual HP slide of a common ocular tumour. Identify the tumour.

(Courtesy Dr Supratik Sanatani - Athena Eye Care)

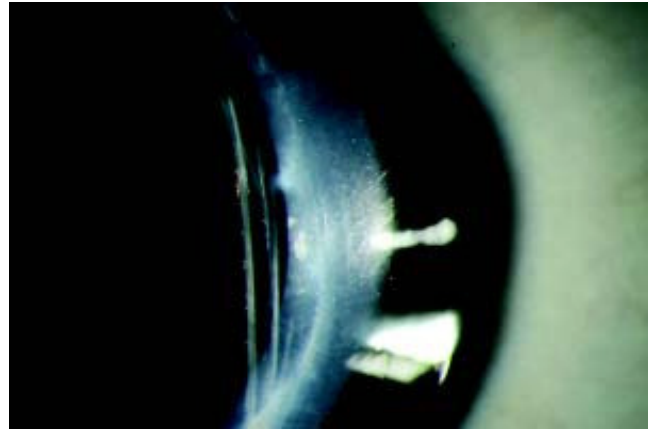
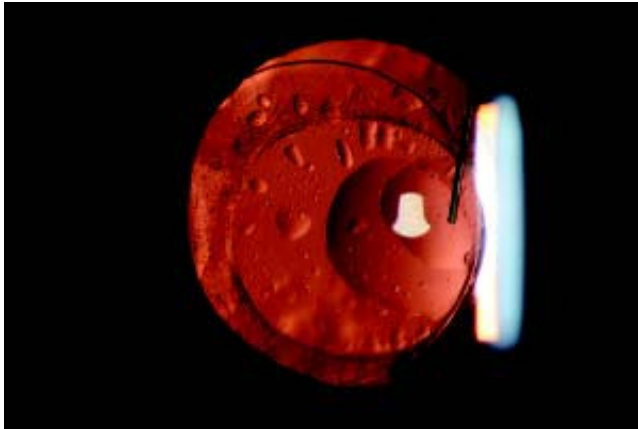
Q6: What is your diagnosis?

(Courtesy Dr Paromita Sanatani - Athena Eye Care)



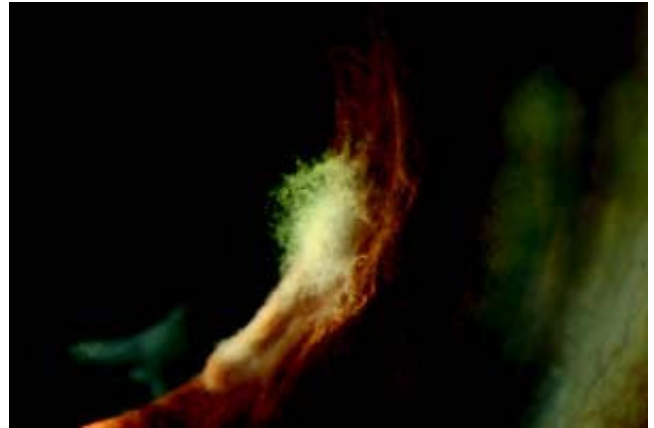
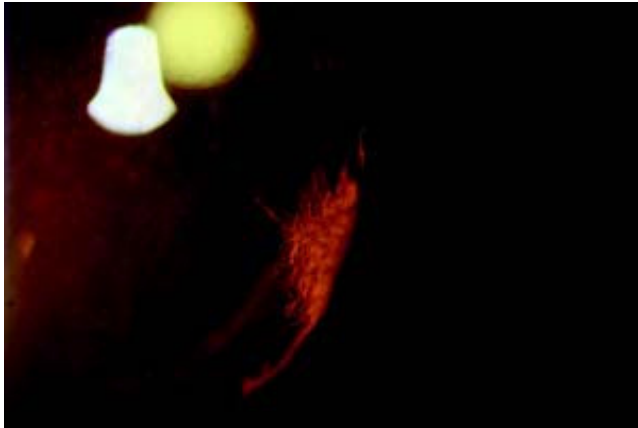Q7. This 18 yrs old male, with moderately high myopia in both eyes, complained of difficulty in night vision. He also had profound deafness since birth and problem with balance. Fundus photo is shown. What is the diagnosis ?

(Courtesy Dr Vivek Dutta - Probal Dutta Memorial Eye Clinic)

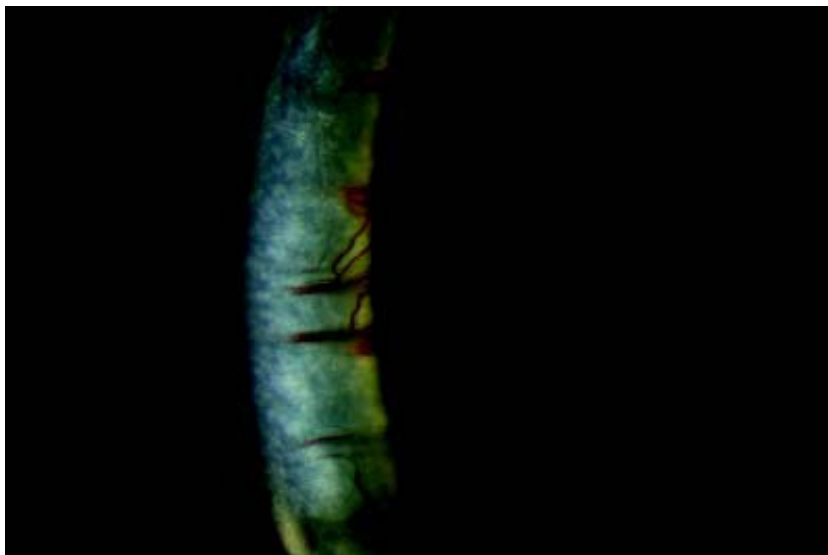

Q8. Patient came in OPD complaining of dimness of vision on 5th post operative day, What is your diagnosis.

Q9. Spot Diagnosis



Q10. 4 month post operative patient who was undergoing chemotherapy for systemic malignancy came with redness and pain in the eye. What is your diagnosis?



Q11. Spot diagnosis

(Q.8-11 Courtesy Dr Arup Bhaumik and Photographs captured by Mr Utpal Sarkar (Disha Eye Hospital))